
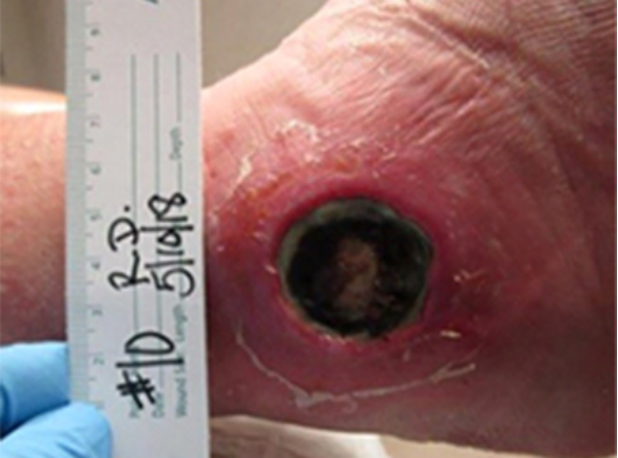


Appendix I: Images and comparisons of different chronic wounds

This table compares different types of chronic wounds to assist health providers in differentiating wounds they may see in clinical practice.

WOUND TYPE	APPEARANCE	SAMPLE IMAGE
<p>Diabetic foot ulcer</p>	<p>Located on plantar aspect of foot, extensive callus formation, superficial to deep</p>	
<p>Arterial ulcer</p>	<p>Deep; eschar; punched-out, well-demarcated borders; deep structures may be exposed</p>	

WOUND TYPE	APPEARANCE	SAMPLE IMAGE
Pressure injury	Located over bony prominences, superficial to deep	
Venous ulcer	Shallow, no eschar; located over medial aspect of lower extremity (gaiter region)	

Source: Adapted with permission from: Bowers S, Franco E. Chronic wounds: evaluation and management. Am Fam Physician [Internet]. 2020 February 1;101(3):159-166. Available from: <https://www.aafp.org/pubs/afp/issues/2020/0201/p159.pdf>